

Body Contouring

High-Intensity Focused Electromagnetic Field With Synchronized Radiofrequency Achieves Superior Gluteal Muscle Contouring Than High-Intensity Focused Electromagnetic Field Procedure Alone

Barry DiBernardo, MD; Suneel Chilukuri, MD, FAAD, FACMS;
JD McCoy, NMD; Bruce Katz, MD; and David J. Goldberg, MD, JD

Aesthetic Surgery Journal Open Forum 2023, 1–8
© The Author(s) 2023. Published by Oxford University Press on behalf of the Aesthetic Society.
This is an Open Access article distributed under the terms of the Creative Commons Attribution-NonCommercial License (<https://creativecommons.org/licenses/by-nc/4.0/>), which permits non-commercial re-use, distribution, and reproduction in any medium, provided the original work is properly cited. For commercial re-use, please contact journals.permissions@oup.com
<https://doi.org/10.1093/asjof/ojac087>
www.asjopenforum.com

OXFORD
UNIVERSITY PRESS

Abstract

Background: The high-intensity focused electromagnetic field (HIFEM) procedure is an effective method for noninvasive toning and shaping of buttocks.

Objectives: To investigate and compare the efficacy of simultaneous application of HIFEM procedure with radiofrequency (RF) heating vs HIFEM standalone procedure on the buttocks.

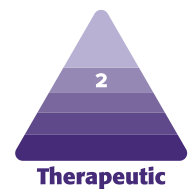
Methods: Sixty-seven subjects (21–67 years, BMI 16–34 kg/m²) were recruited and divided into two groups. Group A received simultaneous HIFEM + RF therapy, and group B received standalone HIFEM treatments. All participants underwent four 30-minute bilateral treatments on the buttocks. The MRI was used to evaluate the changes in muscle and fat thickness.

Results: Data of 32 subjects from group A and 31 subjects from group B were reviewed at 1-month follow-up. On average, subjects from group A showed a 31.3% higher increase in muscle thickness, as shown in the MRI evaluation. The gluteal muscle thickness continued to grow and peaked at a 3-month follow-up, wherein 27 patients were evaluated in each group ($n = 54$). Group A showed on average +24.7% increase (gluteus maximus $+8.5 \pm 1.9$ mm, medius $+6.0 \pm 1.1$ mm, minimus $+2.9 \pm 0.8$ mm), while group B exhibited only +15.9% increase in muscle thickness (gluteus maximus $+5.2 \pm 1.1$ mm, medius $+3.6 \pm 1.0$ mm, minimus $+1.6 \pm 0.4$ mm). On average, group A showed a 35.6% higher growth in muscle thickness. Treatments were safe and comfortable with high satisfaction rates. No adverse event was reported throughout the study.

Conclusions: Our results suggest that simultaneous use of HIFEM + RF is safe and significantly more effective for gluteal contouring than the HIFEM procedure alone.

Level of Evidence: 2

Editorial Decision date: September 15, 2022; online publish-ahead-of-print January 10, 2023.



Dr DiBernardo is the medical director of a private plastic surgery practice, New Jersey, NY, USA. Dr Chilukuri is the medical director of a private dermatology practice, Houston, TX, USA. Dr McCoy is the founder of a private medical practice, Gilbert, AZ, USA. Dr Katz is a clinical professor of dermatology at a private practice, New York, NY,

USA. Dr Goldberg is the director of a private dermatology practice, New York, NY, USA.

Corresponding Author:

Dr Barry DiBernardo, 29 Park St Montclair, NJ 07042, USA.
E-mail: drd@njpsmd.com; Instagram: @newjerseyplasticsurgery

Physical appearance is getting more important in everyday life and social media, where many focus on promoting the topics related to body image and active lifestyle, influencing the individuals who wish to reach for this new standard of beauty.¹ The hectic lifestyle of the modern age, lack of time for exercise, and one's desire for prompt results are all the reasons that drive the demand for effective aesthetic procedures.

Aesthetically pleasing buttocks are considered an essential attribute of beauty,² and according to 2021 statistics of the American Society for Aesthetic and Plastic Surgery, buttocks contouring was up 37% compared to the year 2020.³ The buttocks contouring may be achieved by utilizing invasive means of sculpting through liposuction, as the most performed type of plastic surgery in the United States,³ fat grafting, or implants. However, all of these procedures are associated with a risk of hematoma, seroma, infection, wound dehiscence, and even embolism.⁴ Furthermore, implants or fat grafting are also accompanied by extended downtime and inconvenience because implants should be replaced every decade. Noninvasive (NIV) buttocks contouring includes exercising and 5 FDA-cleared technologies for body contouring: cryolipolysis, lasers, focused ultrasound, radiofrequency, and high-intensity focused electromagnetic field (HIFEM) treatments. Apart from the notable safety of NIV contouring, such technologies have proven to be effective as well, therefore gaining increased attention from patients in recent years.⁵

The most recent NIV technology introduced for body contouring relies on the concomitant HIFEM procedure with synchronized radiofrequency (RF). As evidenced in abdomen,⁶ RF heating primarily targets the subcutaneous tissue causing apoptosis of the fat cells where the fat temperature is elevated and sustained in the range of 42 to 45°C⁷⁻⁹ for most of the therapy time. The main principle of the HIFEM modality is based on alternating magnetic fields of high magnitude (1.8 Tesla units), which depolarizes neuromuscular tissue, thus inducing so-called supramaximal muscle contraction. This brain-independent type of contraction forces the muscle to adapt, activating muscle hypertrophy and hyperplasia, inducing myofibrils growth in size and numbers, respectively.¹⁰ It has been researched that the effect on muscle tissue may be further promoted when heated with RF up to 40°C.¹¹ This increases the blood circulation within the targeted muscle tissue. The supra-maximal muscle contractions create an increased need for energy.¹¹ The RF effect causes the increased blood flow in the tissue, thereby boosting oxygen and nutrient supply in the muscle, enhancing muscle tissue regenerative processes.¹² Synergetic application of HIFEM and RF leads to increased activation of satellite cells (SCs), which, upon activation, regenerate and strengthen the existing

muscle fibers through differentiation.¹³ As the study by Halaas et al¹³ concluded, the HIFEM + RF treatment course is comparable with the results of 12- to 16-week intense exercise programs, delivering the significant muscle enhancement applicable in body contouring.

The three gluteal muscles are the gluteus maximus, medius, and minimus.¹⁴ These muscles have an anatomical function as abductors and adductors of the thigh, and aesthetic function, with the gluteus maximus as the largest muscle contributing to the shape and form of the buttocks the most. With age, the muscles lose their strength and volume, which leads to a less pleasing appearance of the buttocks and lower self-esteem.^{15,16}

Thus, we hypothesize that the simultaneous use of HIFEM and RF technology on the buttocks may induce similar muscle activity patterns as seen on the abdomen, resulting in more pronounced muscle enhancement when compared to HIFEM only. Therefore, this study aims to investigate and compare the effect of HIFEM + RF treatment with a standalone HIFEM procedure on the buttocks.

METHODS

This prospective, multi-center, open-label, two-arm study was approved by the IRB, registered at ClinicalTrials.gov (NCT04871503). The study was initiated in January 2020 and completed in January 2022. Procedures were done according to ethical principles stated in the Declaration of Helsinki. Patients eligible for the study were above the age of 21 years, below the BMI of 35 kg/m², not pregnant, without any metal or electronic objects and implants, and not exhibiting any other condition that contradicts the use of HIFEM + RF fields. Subjects who did not meet the inclusion criteria were excluded. All patients who participated in this study signed written informed consent before enrolling.

Sixty-seven subjects (mean age 38.6 ± 11.6, 21-67 years and BMI 16.0-34.0 kg/m²) were recruited, divided into two groups, and treated by Emsculpt Neo device (BTL Industries Inc., Boston, MA), equipped with two applicators emitting HIFEM + RF fields. In group A, 34 patients with a mean age of 38.4 ± 10.3 years (21-57 years) and BMI 24.3 ± 4.2 kg/m² (16-34.0 kg/m²) received bilateral synergetic treatments over the buttocks with HIFEM and RF intensities set just below the patient's tolerance threshold. The gentle RF preset that maintains sub-apoptotic tissue temperature was used in all subjects from group A. Group B consisted of 33 patients aged on average 38.9 ± 13.3 years (23-67 years) with BMI 23.2 ± 5.5 kg/m² (17.4-31.7 kg/m²). Similar to group A, they received bilateral buttock treatments with energy settings modulated according to the patient feedback. However, only the HIFEM field was active during

Table 1. Treatment Results (Mean in mm \pm SD) and Difference (Increase in %)

Treatment groups		Gluteus maximus		Gluteus medius		Gluteus minimus	
		Group A	Group B	Group A	Group B	Group A	Group B
1-month follow-up data Group A: $n = 32$ Group B: $n = 31$	Baseline	34.9 \pm 7.3	32.6 \pm 6.0	24.7 \pm 4.4	22.8 \pm 6.1	12.2 \pm 2.6	10.6 \pm 2.3
	1 month	41.7 \pm 8.6 (+19.4%)	37.0 \pm 6.8 (+13.4%)	29.3 \pm 5.0 (+18.6%)	25.8 \pm 6.9 (+12.9%)	14.4 \pm 3.1 (+18.3%)	11.9 \pm 2.4 (+12.5%)
3-month follow-up data Group A: $n = 27$ Group B: $n = 27$	Baseline	33.8 \pm 6.0	32.7 \pm 6.0	24.9 \pm 4.0	23.2 \pm 6.1	11.8 \pm 2.6	10.7 \pm 2.3
	3 months	42.3 \pm 7.3 (+25.2%)	37.9 \pm 6.7 (+16.2%)	30.9 \pm 4.5 (+24.46%)	26.8 \pm 6.8 (+15.9%)	14.7 \pm 3.3 (+24.4%)	12.3 \pm 2.4 (+15.6%)

SD, standard deviation.

the treatments. The treatment protocol in both groups consisted of four 30-minute sessions administered in a prone position, spaced 5 to 10 days apart. The therapist checked for simultaneous contraction of gluteal muscles while ensuring the safe placement by avoiding the placement directly over the pelvic skeleton. There were two follow-up visits, 1 month, and 3 months posttreatment, to assess treatment outcomes.

The primary outcome was to assess changes in the gluteus musculus maximus, medius, and minimus thickness through MRI. Scans were performed and evaluated at baseline and both follow-up visits. Using a conventional 1.5 T MRI, fast axial spin-echo (T2 AX FSE) images, scans from the iliac crest to the upper third of the femur were acquired in digital imaging and communication format. Scanning protocol was set with regard to muscle tissue¹⁷⁻¹⁹ as follows: repetition time (TR) 6040 ms, echo time (TE) 30 ms, a slice thickness 5 mm, spacing 6 mm, matrix size 512 \times 512, and field of view (FOV) sufficient to capture the whole scanned area. When acquiring the MRI, patients were positioned in the prone position, so the anterior superior iliac spine was parallel to the bed²¹ to avoid compression of buttock contour. The gluteus medius and minimus measurements were taken at the level of the inferior point of the sacroiliac joint, and thickness of the gluteus maximus was measured at the level just above the femoral head.²⁰ At both measurement levels, the thickness of the adjacent fat layer was assessed as well. All measurements were performed on both glutes, averaged, and compared to baseline.

Patient data on weight, BMI, and digital photographs were taken at baseline, after the last treatment, and at the follow-up sessions. Subjects were instructed to maintain a regular diet and exercise routine to avoid possible bias due to the severe lifestyle changes, which was monitored via a Lifestyle questionnaire filled out at both follow-up visits. After each treatment, patients were asked to fill out a Therapy Comfort Questionnaire (TCQ) consisting of numerical evaluation of comfort (5-point Likert scale) and pain (10-point Visual Analog Scale; VAS) perception with the treatments. At the last treatment visit and both follow-

up visits, patients were also asked to fill in the Subject Satisfaction Questionnaire (SSQ) graded by a 5-point Likert scale, documenting the subject's satisfaction with the achieved results. Adverse events and side effects were monitored throughout the study.

The statistical analysis was performed using the Real Statistics Resource Pack software for Microsoft Excel (Microsoft, Redmond, WA).²¹ The paired differences between the values of individual subjects were tested by using 1 factor Analysis of variance (ANOVA) repeated measures followed by Tukey honestly significant difference (HSD) posthoc test. In addition, a two-tailed independent *t*-test was used to identify the significance between the group's results at particular visits. The significance level α was set at 5% for all statistical tests.

RESULTS

Sixty-seven patients were enrolled (64 females and 3 males), while 65 patients completed all treatments. At 1-month and 3-month follow-ups, the data of 63 and 54 patients were assessed, respectively. In both groups, the BMI (and weight) fluctuations turned out to be minor and insignificant throughout the study ($P > .05$).

Muscle Thickness Measurements

In group A ($n = 32$), the overall muscle thickness significantly increased on average by 18.8% ($P < .001$) at 1 month. The biggest change was observed in the gluteus maximus, where on average, this muscle increased in thickness by 19.42% ($+6.7 \pm 2.0$ mm). In group B ($n = 31$), the average increase was 12.9% at 1-month follow-up ($P < .001$), again showing the highest absolute and relative increase in gluteus maximus (+13.4%; $+4.3 \pm 1.5$ mm). At the 1-month follow-up, subjects from group A showed, on average, by 31.3% higher relative increase when compared to group B. The results in muscle thickness continued to grow at 3-month follow-up, when patients in group A ($n = 27$) showed

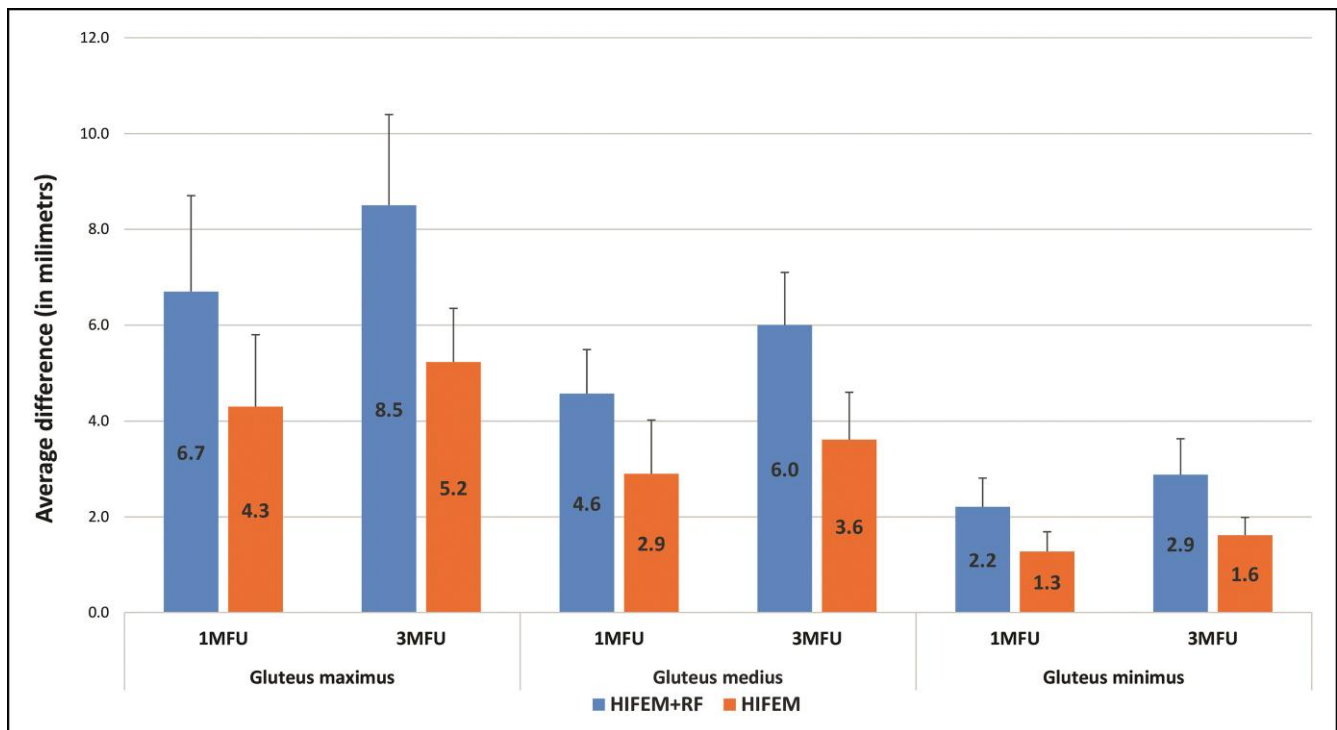


Figure 1. Difference in gluteal muscles at 1-month follow-up and 3-month follow-up, with error bars representing the SD (in mm). Reproduced with permission from BTL Industries. HIFEM, high-intensity focused electromagnetic field; RF, radiofrequency.

on average 35.6% higher relative increase than in group B ($n = 27$), with a significant difference in all gluteal muscles between the groups. In particular, the mean change in group A averaged at 24.7% ($P < .001$), while group B reached an average improvement of 15.9% ($P < .001$). As noted at 1 month, the gluteus maximus also showed the highest values at 3 months, followed by the gluteus medius and minimus. More detailed information can be found in Table 1 and Figure 1. There were no statistically significant differences between the groups at baseline ($P > .05$), nonetheless as the study progressed, the differences became significant in all measured muscles, including gluteus maximus: ($P = .02$ and $P < .01$ at 1 and 3 months) gluteus medius and gluteus minimus as well ($P < .01$ at both follow-ups). The evaluation of digital photographs showed the aesthetic improvement of buttocks in terms of lifting, shape, and firmness in both groups, with greater improvement in both shape and lifting effect in group A (Figures 2-4). The MRI evaluation supported the findings in digital photographs (Figures 5, 6).

Fat Thickness Measurements

Subcutaneous fat layer values showed both clinically and statistically insignificant ($P > .05$) changes at both follow-ups in each group. The average change of fat layer in group A was $-0.2 \pm 1.4\%$ (range from -2.4 mm to $+0.7$ mm) at 1-month follow-up, while in group B the change was $+0.2 \pm 1.5\%$ (from

-1.1 mm to $+1.4$ mm). At 3-month follow-up, the average change in group A was $-0.1 \pm 1.4\%$ (from -1.7 mm to $+0.7$ mm), with $-0.2 \pm 1.0\%$ (from -0.9 mm to $+0.4$ mm) in group B.

Questionnaires

According to the TCQ and the SSQ, both groups found the therapy comfortable and painless, and patients were satisfied with the results. According to the TCQ, both groups agreed with the statement that the treatment was comfortable, and both groups found the treatment painless based on the VAS (group A: 1.3 ± 1.9 points and group B: 1.2 ± 1.7 points). The SSQ consisted of 3 questions, where the evaluation of the results showed that in both groups, more than 84% of the patients agreed that their appearance had improved, more than 93% of the patients noticed toning in the treated area, and more than 84% of patients were satisfied with the results. In addition, no adverse events, side effects, or complications were reported.

DISCUSSION

Toning of the gluteal muscles has functional roles in preventing injury because of ankles' and spine overuse and in enhancing functional capacity during running and walking,²² because muscle mass correlates with muscle

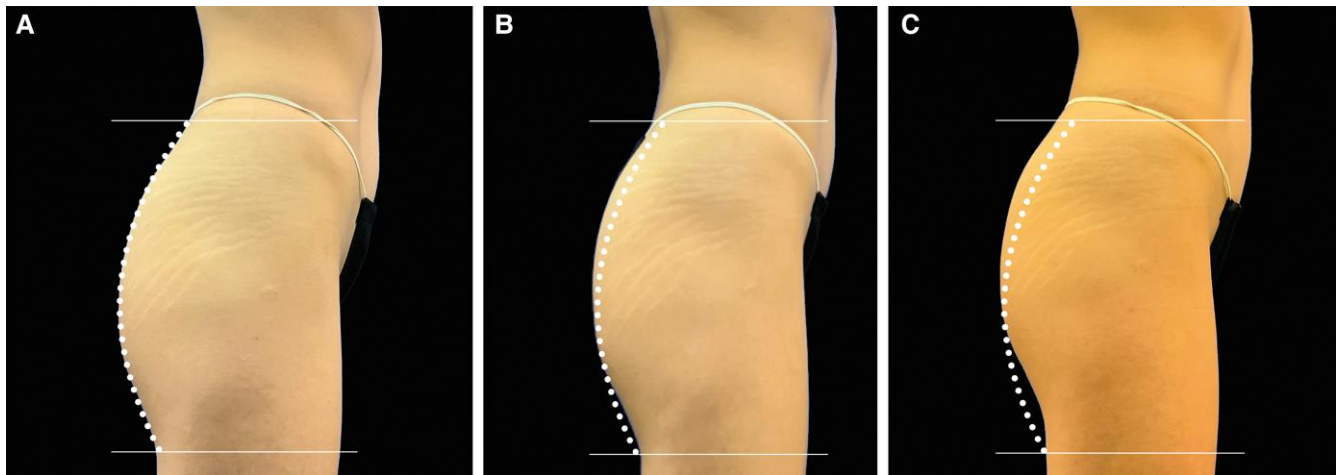


Figure 2. A 23-year-old female with a BMI of 17.3 kg/m², treated with high-intensity focused electromagnetic field (HIFEM) only, comparison of digital photos taken (A) at baseline, (B) after the fourth treatment, and (C) at 3-month follow-up (the average increment of muscle thickness by 14.6%). The dotted line represents the shape of the buttocks at baseline. Reproduced with permission from BTL Industries.

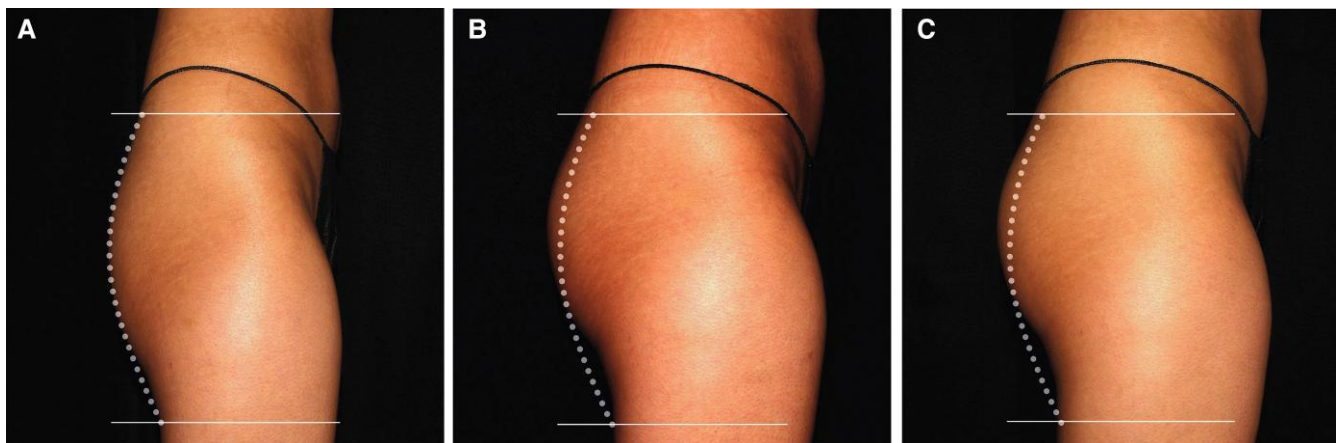


Figure 3. A 21-year-old female with a BMI of 21.3 kg/m², treated with combination RF + HIFEM, comparison of digital photos taken (A) at baseline, (B) after the fourth treatment, and (C) at 3-month follow-up (the average increment of muscle thickness by 22.8%). The dotted line represents the shape of the buttocks at baseline. Reproduced with permission from BTL Industries. HIFEM, high-intensity focused electromagnetic field; RF, radiofrequency.

strength.²³ On the other hand, it also influences the overall appearance of the buttocks and self-esteem of some individuals.

In this study, the treatments with a novel device, either combining HIFEM and synchronized RF or using stand-alone HIFEM treatments, resulted in significant gluteal muscle growth without reducing subcutaneous fat tissue. The observed outcomes in muscle thickness were gradually improving and peaked at a 3-month follow-up. Group A, treated with simultaneous use of HIFEM + RF, showed a greater improvement in muscle thickness at both follow-up visits (by 31.3% at 1 month and by 35.6% at 3 months) than group B, which was treated with HIFEM procedure only.

The benefits of the HIFEM treatment on buttocks were already described in preceding studies. Initially, the

researchers evaluated the concept of such treatment of buttocks, focusing on the assessment of digital photographs and subjective response.²⁴⁻²⁶ Correspondingly, patients described the treatment as comfortable with high satisfaction levels in all questions. In the most recent MRI study by Palm,²⁷ 7 women underwent treatment using stand-alone HIFEM. By conducting a 3D analysis of gluteal muscles, she has found 13.23% ± 0.91% average volume enhancement of the gluteal muscles at a 3-month follow-up. Although a different methodology of assessing MRI scans was used when compared to this study, the relative increase found by Palm²⁷ is roughly comparable to the results mentioned above in our HIFEM only group, yet slightly lower (group B, +15.9% increase at 3 months). Given the

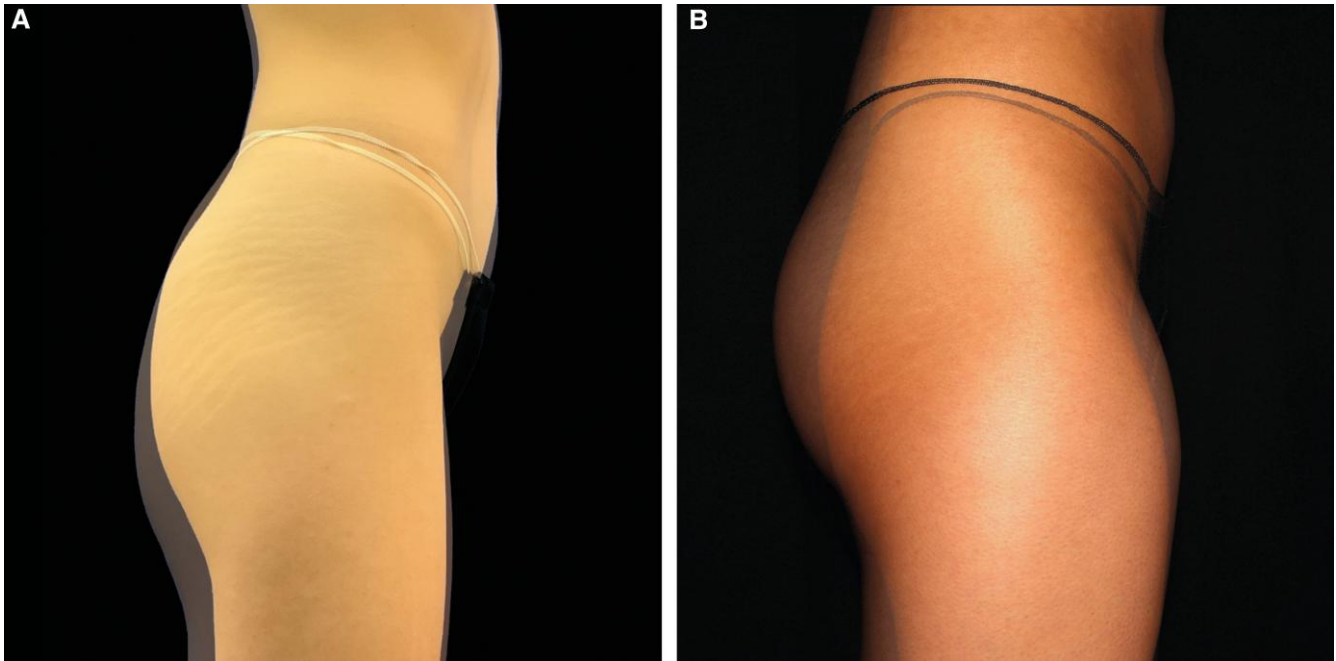


Figure 4. The overlap of baseline and 3-month follow-up digital photos from Figures 2 and 3. There is a visible improvement in both groups with a more pronounced shaping and lifting effect in group treated with the combination of HIFEM + RF (part B) than group treated with HIFEM only (part A). Reproduced with permission from BTL Industries.

results of group A (+24.7% on average at 3 months), one may suggest that the volumetric increase in gluteal muscle mass may be even higher when HIFEM and synchronized RF are used simultaneously.

In our study, group A was treated with the combination of HIFEM + RF, where the RF component was set to gentle preset, ensuring that the adipose tissue in the treated area was not heated to apoptotic temperatures. The results show that fat tissue was not affected significantly, with negligible and comparable changes observed in both groups. Moreover, it has been shown that the buttock's fatty tissue has a different lipolytic activity because the fat cells in the gluteal area are more responsive to alpha 2-adrenergic agonists.²⁸ These neurotransmitters have an antilipolytic function and make the lipolytic processes in the buttock's fatty tissue significantly less active,²⁹ which may explain the mild changes in fat thickness seen in this study, regardless of the used modality.

This study's main strength is the MRI evaluation of changes in muscle thickness because the MRI provides spatial and detailed enough contrast resolution for the evaluation of individual muscles.³⁰ Further strengths include a large number of enrolled patients allocated into 2 groups that could be compared with each other. Although 13 patients did not attend their MRI appointment at 3 months (7 patients from group A, 6 patients from group B), the sample size was still large enough for the statistics to be conclusive. However, further studies are needed to fully understand the processes

in gluteal fatty tissue while treated with HIFEM or HIFEM + RF. The limitations of the study include unequal gender representation, with only 3 treated males, use of a single measuring method being the linear muscle thickness measurements, and inexact replication of photographing conditions due to lighting levels and subject's posture, possibly affecting the readability of the resulting images. Future studies should focus on recruiting a greater number of male patients to verify and compare the effect on both sexes and conduct a more rigorous evaluation of muscle tissue, such as a change in volume. The subject photographs should be standardized and taken under uniform conditions at every visit, to enable proper visualization of the treated area. Moreover, it may be considered to extend the follow-up period to document the persistence and nature of achieved outcomes in the long-term with an emphasis on the particular needs of the subjects.

CONCLUSIONS

The primary aim of this study was to compare a simultaneous application of the HIFEM + RF energy vs the standalone HIFEM procedure for its effectiveness, safety and overall effect on buttock contouring. The results revealed the greater efficiency of simultaneous application of HIFEM + RF in terms of superior increase in gluteal muscle thickness. Furthermore, high patient satisfaction and overall

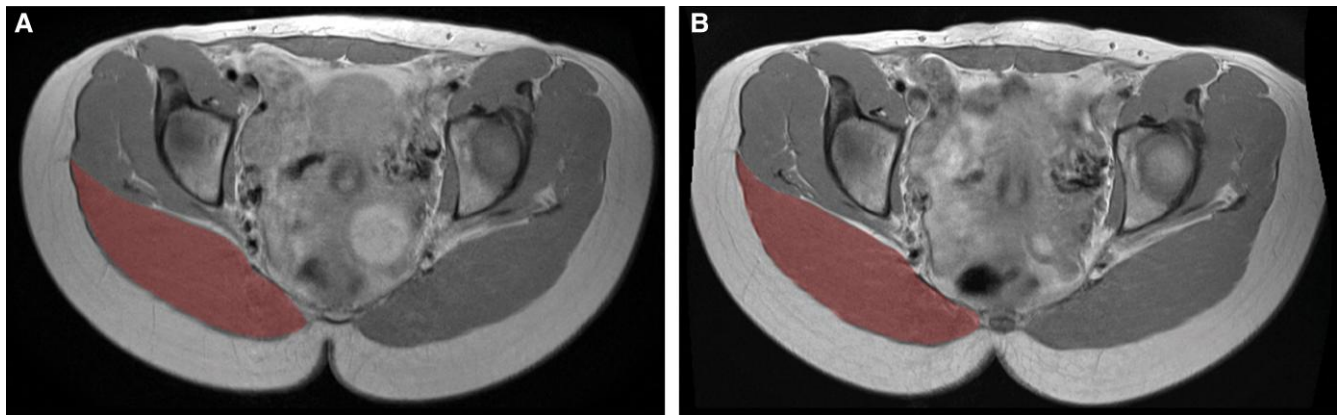


Figure 5. The MRI scan of the 21-year-old female from Figure 3, MRI scans taken (A) at baseline and (B) at 3-month follow-up. The highlighted part represents the changes that occurred in gluteus maximus (red) during the study. Reproduced with permission from BTL Industries.

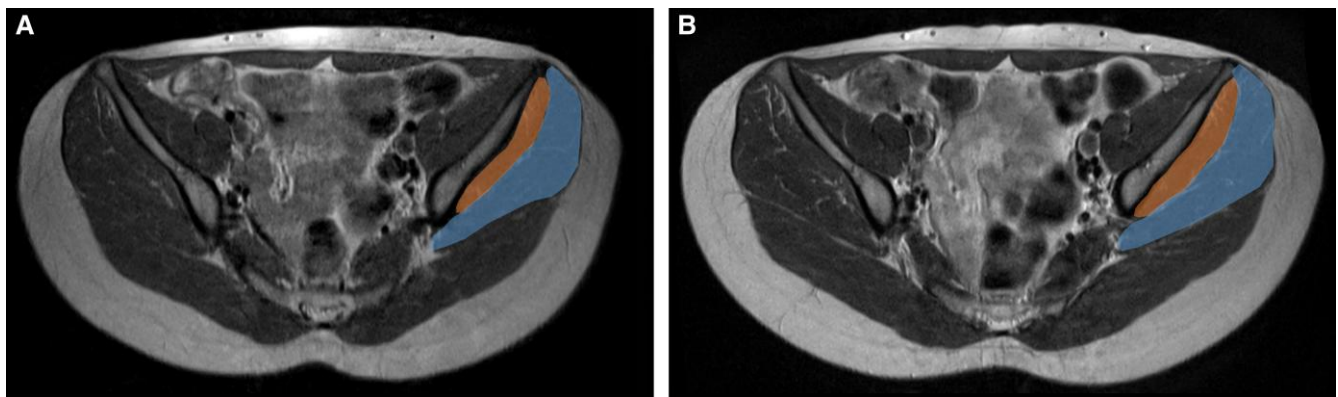


Figure 6. The MRI scan of the 21-year-old female from Figure 3, MRI scans taken (A) at baseline and (B) at 3-month follow-up. The highlighted part represents the changes that occurred in the gluteus medius (blue) and gluteus minimus (orange) during the study. Reproduced with permission from BTL Industries.

enhancement of buttock contour and appearance were documented. There were no significant changes in gluteal adipose tissue, and no adverse events occurred in both groups.

Disclosures

Drs DiBernardo, Chilukuri, McCoy, Katz, and Goldberg are clinical investigators for BTL Industries, Inc. (Boston, MA).

Funding

This multicenter study was sponsored by BTL Industries.

REFERENCES

1. Salomon I, Brown CS. The selfie generation: examining the relationship between social media use and early adolescent body image. *J Early Adolescence*. 2019;39(4):539-560. doi: [10.1177/0272431618770809](https://doi.org/10.1177/0272431618770809)
2. Fisher ML, Voracek M. The shape of beauty: determinants of female physical attractiveness. *J Cosmet Dermat*. 2006;5(2):190-194. doi: [10.1111/j.1473-2165.2006.00249.x](https://doi.org/10.1111/j.1473-2165.2006.00249.x)
3. The aesthetic society's cosmetic surgery national data bank: statistics 2021. *Aesthet Surg J*. 2022;42(Suppl_1):1-18. doi: [10.1093/asj/sjac116](https://doi.org/10.1093/asj/sjac116)
4. Rohrich RJ, Mendez BM, Afroz PN. An update on the safety and efficacy of outpatient plastic surgery: a review of 26,032 consecutive cases. *Plastic Reconstr Surg*. 2018;141(4):902-908. doi: [10.1097/PRS.0000000000004213](https://doi.org/10.1097/PRS.0000000000004213)
5. Rzepecki AK, Farberg AS, Hashim PW, Goldenberg G. Update on noninvasive body contouring techniques. *Cutis*. 2018;101(4):285-288.
6. Jacob C, Kent D, Ibrahim O. Efficacy and safety of simultaneous application of HIFEM and synchronized radiofrequency for abdominal fat reduction and muscle toning: a multicenter magnetic resonance imaging evaluation study. *Dermatol Surg*. 2021;47(7):969-973. doi: [10.1097/DSS.0000000000003086](https://doi.org/10.1097/DSS.0000000000003086)

7. Franco W, Kothare A, Goldberg D. Controlled volumetric heating of subcutaneous adipose tissue using a novel radiofrequency technology. *Lasers Surg Med.* 2009;41(10):745-750. doi: [10.1002/lsm.20876](https://doi.org/10.1002/lsm.20876)
8. Weiss RA, Bernardy J, Tichy F. Simultaneous application of high-intensity focused electromagnetic and synchronized radiofrequency for fat disruption: histological and electron microscopy porcine model study. *Dermatol Surg.* 2021;47(8):1059-1064. doi: [10.1097/DSS.0000000000003091](https://doi.org/10.1097/DSS.0000000000003091)
9. Goldberg DJ. Deletion of adipocytes induced by a novel device simultaneously delivering synchronized radiofrequency and HIFEM: human histological study. *J Cosmetic Dermatol.* 2021;20(4):1104-1109. doi: [10.1111/jocd.13970](https://doi.org/10.1111/jocd.13970)
10. Duncan D, Dinev I. Noninvasive induction of muscle fiber hypertrophy and hyperplasia: effects of high-intensity focused electromagnetic field evaluated in an in-vivo porcine model: a pilot study. *Aesthet Surg J.* 2020;40(5):568-574. doi: [10.1093/asj/sjz244](https://doi.org/10.1093/asj/sjz244)
11. Duncan D, Chilukuri S, Kent D, Hoffmann K, Tingsong L. Non-invasive alternatives for liposuction. In: *Enhanced Liposuction - New Perspectives and Techniques [Working Title]*. IntechOpen; 2022. doi: [10.5772/intechopen.101396](https://doi.org/10.5772/intechopen.101396)
12. Giombini A, Giovannini V, Cesare AD, et al. Hyperthermia induced by microwave diathermy in the management of muscle and tendon injuries. *Br Med Bull.* 2007;83(1):379-396. doi: [10.1093/bmb/ldm020](https://doi.org/10.1093/bmb/ldm020)
13. Halaas Y, Duncan D, Bernardy J, Ondrackova P, Dinev I. Activation of skeletal muscle satellite cells by a device simultaneously applying high-intensity focused electromagnetic technology and novel RF technology: fluorescent microscopy facilitated detection of NCAM/CD56. *Aesthet Surg J.* 2021;41(7):NP939-NP947. doi: [10.1093/asj/sjab002](https://doi.org/10.1093/asj/sjab002)
14. Elzanie A, Borger J. Anatomy, Bony Pelvis and Lower Limb. Gluteus maximus muscle. In: *StatPearls*. StatPearls Publishing; 2021. Accessed December 17, 2021. <http://www.ncbi.nlm.nih.gov/books/NBK538193/>
15. Keller K, Engelhardt M. Strength and muscle mass loss with aging process. Age and strength loss. *Muscles Ligaments Tendons J.* 2013;3(4):346-350. doi: [10.32098/mltj.04.2013.17](https://doi.org/10.32098/mltj.04.2013.17)
16. Volpi E, Nazemi R, Fujita S. Muscle tissue changes with aging. *Curr Opin Clin Nutr Metab Care.* 2004;7(4):405-410. doi: [10.1097/O1.mco.0000134362.76653.b2](https://doi.org/10.1097/O1.mco.0000134362.76653.b2)
17. Kivle K, Lindland E, Mjaaland KE, Pripp AH, Svenningsen S, Nordsletten L. The gluteal muscles in end-stage osteoarthritis of the hip: intra- and interobserver reliability and agreement of MRI assessments of muscle atrophy and fatty degeneration. *Clin Radiol.* 2018;73(7):675.e17-675.e24. doi: [10.1016/j.crad.2018.02.014](https://doi.org/10.1016/j.crad.2018.02.014)
18. Müller M, Tohtz S, Winkler T, Dewey M, Springer I, Perka C. MRI findings of gluteus minimus muscle damage in primary total hip arthroplasty and the influence on clinical outcome. *Arch Orthop Trauma Surg.* 2010;130(7):927-935. doi: [10.1007/s00402-010-1085-4](https://doi.org/10.1007/s00402-010-1085-4)
19. Pfirrmann CWA, Notzli HP, Dora C, Hodler J, Zanetti M. Abductor tendons and muscles assessed at MR imaging after total hip arthroplasty in asymptomatic and symptomatic patients. *Radiology.* 2005;235(3):969-976. doi: [10.1148/radiol.2353040403](https://doi.org/10.1148/radiol.2353040403)
20. Homma D, Minato I, Imai N, et al. Appropriate sites for the measurement of the cross-sectional area of the gluteus maximus and the gluteus medius muscles in patients with hip osteoarthritis. *Surg Radiol Anat.* 2021;43(1):45-52. doi: [10.1007/s00276-020-02535-2](https://doi.org/10.1007/s00276-020-02535-2)
21. Citation for the Real Statistics Software or Website | Real Statistics Using Excel. Accessed January 18, 2022. <https://www.real-statistics.com/appendix/citation-real-statistics-software-website/>.
22. Liebenow C. Functional training of the gluteal muscles. *J Bodyw Mov Ther.* 2009;13(2):202-204. doi: [10.1016/j.jbmt.2009.01.004](https://doi.org/10.1016/j.jbmt.2009.01.004)
23. Reed RL, Pearlmutter L, Yochum K, Meredith KE, Mooradian AD. The relationship between muscle mass and muscle strength in the elderly. *J Am Geriatrics Soc.* 1991;39(6):555-561. doi: [10.1111/j.1532-5415.1991.tb03592.x](https://doi.org/10.1111/j.1532-5415.1991.tb03592.x)
24. Giesse S. A German prospective study of the safety and efficacy of a non-invasive, high-intensity, electromagnetic abdomen and buttock contouring device. *J Clin Aesthet Dermatol.* 2021;14(1):30-33.
25. Jacob C, Kinney B, Busso M. High intensity focused electromagnetic technology (HIFEM) for non-invasive buttock lifting and toning of gluteal muscles: a multi-center efficacy and safety study. *J Drugs Dermatol.* 2018;17(11):1229-1232.
26. Busso M, Denkova R. High-intensity focused electromagnetic (HIFEM) field therapy used for non-invasive buttock augmentation and lifting: feasibility study. Undefined. Published online 2019. Accessed November 1, 2021. [https://www.semanticscholar.org/paper/High-Intensity-Focused-Electromagnetic-\(HIFEM\)-Used-Busso-Denkova/72caa6ec7c4ac1052c31958765ba1015d7cace7e](https://www.semanticscholar.org/paper/High-Intensity-Focused-Electromagnetic-(HIFEM)-Used-Busso-Denkova/72caa6ec7c4ac1052c31958765ba1015d7cace7e)
27. Palm M. Magnetic resonance imaging evaluation of changes in gluteal muscles after treatments with the high-intensity focused electromagnetic procedure. *Dermatol Surg.* 2021;47(3):386-391. doi: [10.1097/DSS.0000000000002764](https://doi.org/10.1097/DSS.0000000000002764)
28. Rosenbaum M, Presta E, Hirsch J, Leibel RL. Regional differences in adrenoceptor status of adipose tissue in adults and prepubertal children. *J Clin Endocrinol Metab.* 1991;73(2):341-347. doi: [10.1210/jcem-73-2-341](https://doi.org/10.1210/jcem-73-2-341)
29. Castan I, Valet P, Quideau N, et al. Antilipolytic effects of alpha 2-adrenergic agonists, neuropeptide Y, adenosine, and PGE1 in mammal adipocytes. *Am J Physiol.* 1994;266(4):R1141-R1147. doi: [10.1152/ajpregu.1994.266.4.R1141](https://doi.org/10.1152/ajpregu.1994.266.4.R1141)
30. Kalia V, Leung D, Sneag D, Grande F, Carrino J. Advanced MRI techniques for muscle imaging. *Semin Musculoskelet Radiol.* 2017;21(4):459-469. doi: [10.1055/s-0037-1604007](https://doi.org/10.1055/s-0037-1604007)